

## SALPINGOHYSTERECTOMY IN A FEMALE BUDGERIGAR (*MELOPSITTACUS UNDULATUS*) DUE TO OVIDUCT IMPACTION

### SALPINGOHISTERECTOMIA NUMA FÊMEA PERIQUITO ONDULADO (*MELOPSITTACUS UNDULATUS*) DEVIDO A UMA IMPACTAÇÃO DO OVIDUCTO

Ana Reinho

VetSet – Clínica Veterinária de Setúbal, Lda. [chica\\_ginja@yahoo.com](mailto:chica_ginja@yahoo.com)

**Abstract:** Female breeding tract disease is common in small psittacine clinical practice. The author makes a brief introduction to these issues, followed by a case report. In the latest, it is described the surgical resolution of oviduct impaction in a female budgerigar (*Melopsittacus undulatus*).

**Resumo:** A patologia reprodutiva é frequente nas fêmeas de Psitacíformes de pequeno porte. No artigo, é feita uma breve abordagem às alterações que podem ser encontradas em clínica destas espécies, seguida da apresentação dum caso de impactação do oviducto numa fêmea de periquito ondulado (*Melopsittacus undulatus*), com especial destaque para a resolução cirúrgica do processo.

## INTRODUCTION

Reproductive problems, such as egg binding and chronic egg laying, are a common issue in small psittacine species, namely cockatiels, budgerigars and lovebirds<sup>2</sup>.

Breeding problems in female psittacines have a multifactorial aetiology, but many causes can be management related. Management deficiencies that can lead to reproductive disease in female psittacine pet birds include: nutritional imbalances (both deficiencies and excesses in calcium, selenium and vitamin E); long photoperiods (over 8 hours of light per day); inadequate environmental temperature and humidity; lack of an adequate place to lay the eggs and inadequate exercise<sup>1</sup>.

Other causes of breeding disease are related to the patient itself. Examples include systemic disease, oviduct muscle weakness, genetic predisposition and oviduct infection<sup>1</sup>.

Egg binding is the failure of an egg to pass through the oviduct within a normal period of

time that is, on average, 48 hours for most pet species<sup>3</sup>. Egg binding may or may not be associated with dystocia – the mechanical or functional obstruction to oviposition in the distal reproductive tract<sup>2</sup>. Both egg binding and dystocia have an acute onset and may be immediately life threatening. On the other hand, chronic egg laying is defined as the laying of larger than normal or repeated clutches, regardless of the presence of a mate or the proper breeding season<sup>2</sup>. Chronic egg laying is not an acute problem, but it is very demanding on the reproductive tract and leads to a serious metabolic drain on calcium stores. In time, chronic egg laying may predispose the female psittacine bird to egg binding, yolk coelomitis and osteoporosis<sup>3</sup>.

Oviduct impaction is the accumulation of eggs or egg material within the oviduct and is usually a consequence of dystocia, metritis or salpingitis<sup>1,3</sup>. Oviduct impactions may also occur due to excessive production of albumin or mucin, in patients with cystic hyperplasia

of the oviduct<sup>3</sup>. Again, this is not an acute disease and clinical signs of oviduct impaction may be vague<sup>3</sup>. Hens with oviduct impaction stop laying eggs, despite the presence of otherwise normal breeding behaviour. They may be systemically ill, cachectic or show abdominal distension<sup>1</sup>. Some may be reluctant to walk or fly and they may have diarrhoea or constipation<sup>3</sup>. The diagnosis of oviduct impaction is achieved through history taking, physical examination, radiography and ultrasonography<sup>1</sup>.

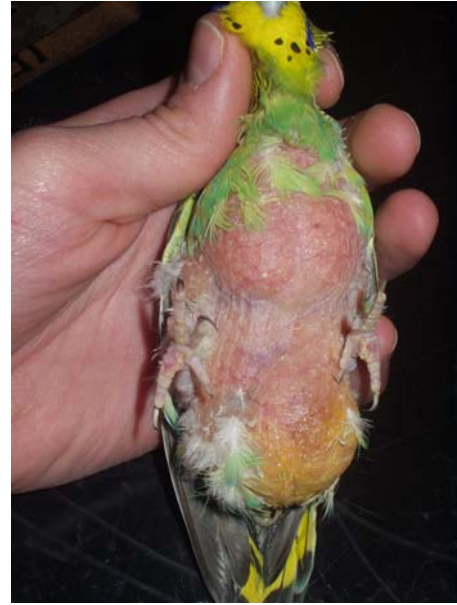Imagiology findings include the presence of a soft tissue density in the region of the oviduct, with displacement of the other coelomic viscera to the right. There may be loss of visceral detail in the presence of coelomitis<sup>3</sup>.

Female avian patients with oviduct impaction require surgery, either to remove the impacted material or to perform salpingohysterectomy<sup>1</sup>. Besides surgery, the treatment of oviduct impactions also includes parenteral fluid therapy, nutritional support, warmth and the administration of broad spectrum antibiotics. It is also very important to stop reproductive activity of the patient, with environmental, medical and/or surgical therapy, to prevent recurrence of oviduct impactions<sup>3</sup>.

### CASE REPORT

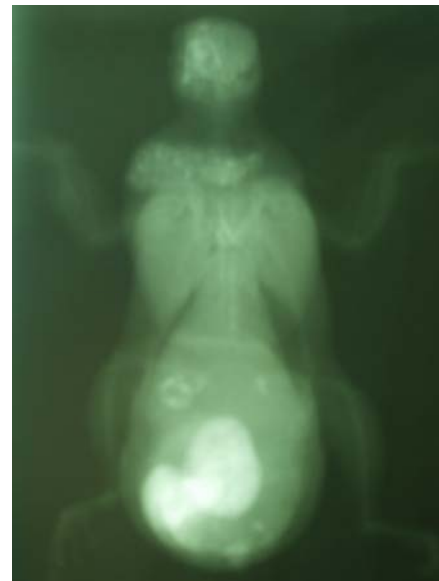The patient was an 8 years old female budgerigar, with severe abdominal distension, that had been developing for the last four months. There was a history of multiple clutches, but the patient hadn't laid any eggs for several months, despite the presence of a very dedicated mate.

Physical examination revealed obesity (76 g body weight), extensive apteria over the chest and abdomen, inability to perch and severe abdominal distension. There was a yellow discoloration of the skin in the lower abdomen. It was possible to palpate a firm mass at the left region of the coelomic cavity. (Fig 1).



**Figure 1.** Patient on presentation

Patient was sent for X-ray that revealed the presence of three abnormally and highly calcified eggs (Fig 2).



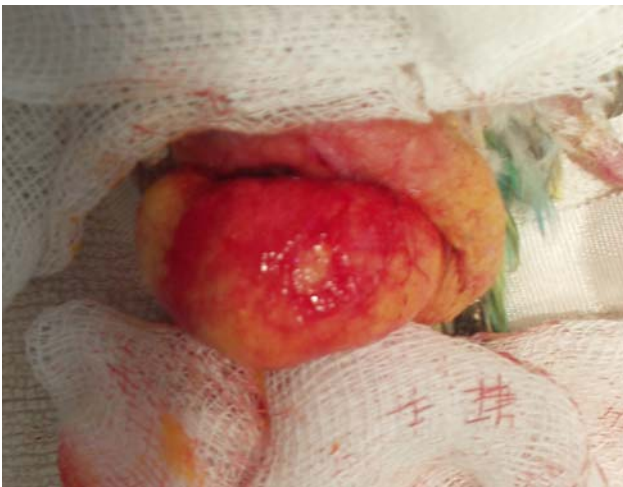**Figure 2.** Ventro-dorsal full body x-ray

In an effort to prevent further ovulation, this patient was given human chorionic gonadotropin (hCG, 400 IU/kg IM twice, three days apart 4). The owner was instructed to reduce photoperiod to no longer than 10 hours of light a day and to remove all available nests. Salpingohysterectomy was scheduled for the fourth day after presentation.

Anaesthesia was induced with isoflurane, in an adapted induction chamber (Fig 3).

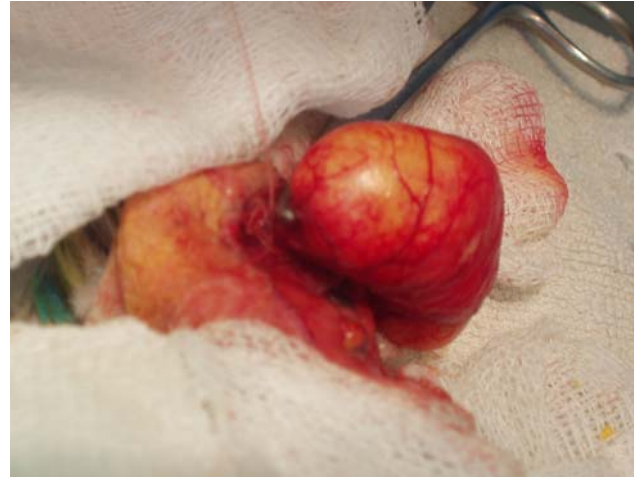

**Figure 3.** Patient in an adapted induction chamber. Maintenance of anaesthesia was made through facial mask. Heat was supplemented throughout the whole procedure with a heating pad. Skin and abdominal muscle were incised at the ventral midline and an impressively distended oviduct was readily seen (Fig 4).



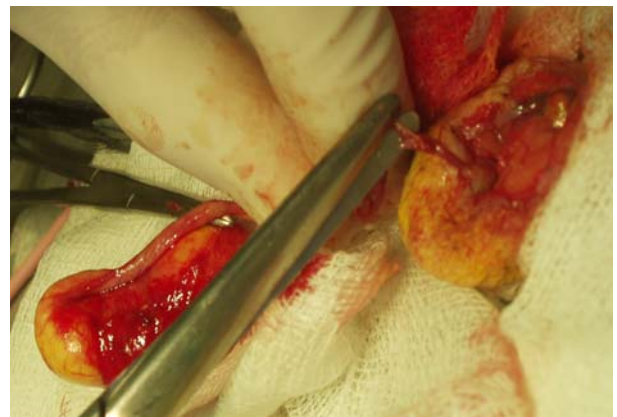
**Figure 4.** Distended oviduct, emerging from the abdominal incision.

For ease of surgical procedure, and because of the extreme dilation of the lower oviduct, removal of this organ was started at its most distal portion (Fig 5).

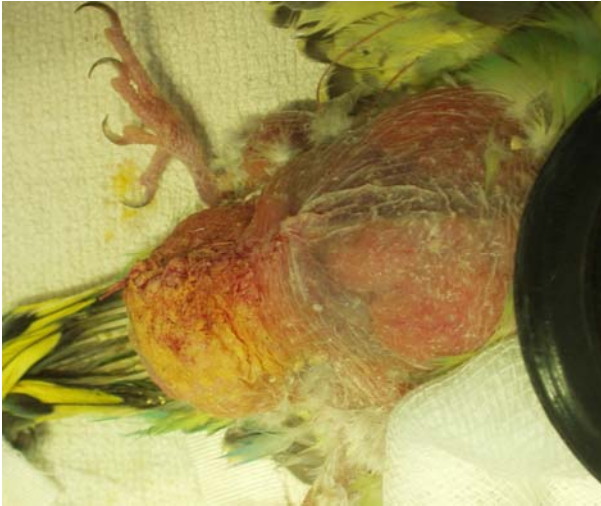


**Figure 5.** Clamping and ligation of the oviduct at its distal portion.

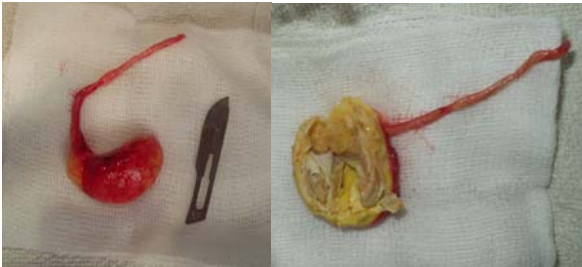All organ and vessel ligations were made manually, with 4/0 Dexon. The oviduct was removed as far proximally as possible (Fig 6). Closure of the abdominal cavity was made in two layers, in a simple uninterrupted pattern (Fig 7). Subcutaneous fluids, meloxicam and enrofloxacin were given at the end of the procedure.



**Figure 6.** Proximal ligation of the oviduct.



**Figure 7.** Patient at the end of the procedure.



**Figure 8.** Removed oviduct, before and after opening (number 10 surgical blade for size comparison).

The patient recovered uneventfully from the anaesthesia and was sent home the very same day, medicated with enrofloxacin (10 mg/kg orally, q12h) and meloxicam (0,2 mg/kg orally, q24h). Unfortunately, the removed oviduct wasn't sent for histopathology and we weren't able to determine if there was any primary disease of the oviduct. However, the organ was opened and there were observed three altered egg remains (Fig8).

Sutures were removed at day 10 and the owner reported a full recovery of the patient. Despite our lack of experience with avian soft tissue surgery and the limitations in specialised material and devices, this proved to be a very resistant patient. Two years after surgery, this female budgerigar is still alive and there haven't been any reports of disease regarding the reproductive system.

## REFERENCES

1. Altman RB, Clubb SL, Dorrestein M, Quesenberry K. Avian Medicine and Surgery, 1st Edition. Philadelphia: Saunders, 1997, p.633-638
2. Romagnano A. Reproduction and paediatrics. In: BSAVA Manual of Psittacine Birds, 2nd Edition, Gloucester, 2005
3. Harrison GJ, Lightfoot TL. Clinical Avian Medicine. Palm Beach: Spix Publishing Inc. 2006
4. Carpenter JW. Exotic Animal Formulary, 3rd Edition. St. Louis: Elsevier Saunders. 2005
5. Kramer M, Harris D. Ventral Midline Approach to Avian Salpingohysterectomy. Exotic DVM 4.4: 23-27, 2002